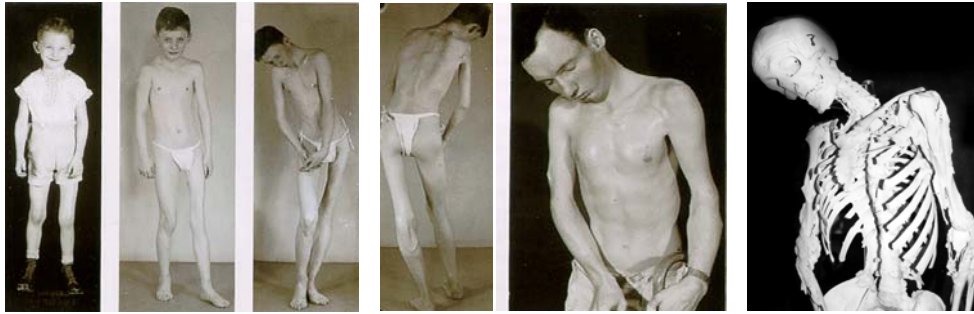


What is Fibrodysplasia Ossificans Progressiva (FOP)? One of the rarest, most disabling genetic conditions known to medicine, it causes bone to form in muscles, tendons, ligaments and other connective tissues. Bridges of extra bone develop across joints, progressively restricting movement and forming a second skeleton that imprisons the body in bone. There are no other known examples in medicine of one normal organ system turning into another.



Age(years) 6 9 11 13 20 40

An example of the typical progression of FOP: Photos of an individual through his lifetime. Spontaneous flare-ups of the disease arise in defined temporal and spatial patterns, resulting in ribbons and sheets of bone that fuse the joints of the axial and appendicular skeleton, entombing a patient in a skeleton of heterotopic bone.

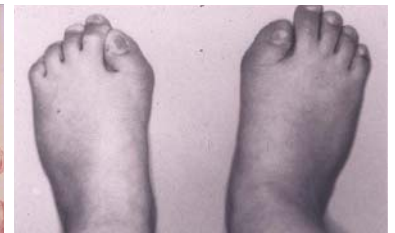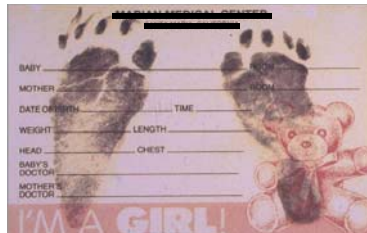
How would understanding the cause of bone formation in FOP help others? The information obtained from studying this disease will have far reaching implications for the treatment of common disorders such as fractures, osteoporosis, hip replacement surgery, and other forms of heterotopic ossification that occur in trauma and burn victims.

Demographics of FOP:

- Genetic disease affecting 1 in 2 million people
- No ethnic, racial, or religious patterns
- 700 confirmed cases across the globe
- 285 known cases in the United States

Clinical Characteristics of FOP:

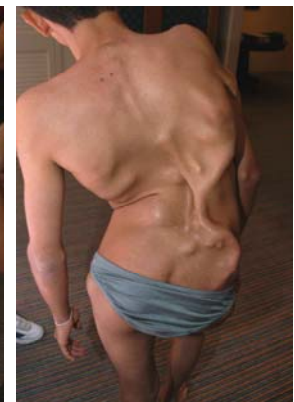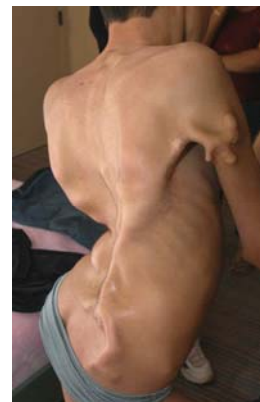- Characteristic malformations of the great toe
- Flare-ups occur spontaneously or following bodily trauma such as: childhood immunizations, falls while playing, viral illnesses
- Misdiagnosed in a majority of cases as cancer
- Surgery makes the condition worse
- There are no effective treatments



Characteristic Toe Abnormality: 95% of children afflicted by FOP have an abnormally formed great toe.

Finding a Cure and Treatment for FOP:

- Researchers at the University of Pennsylvania School of Medicine, the only laboratory in the US dedicated to FOP research, announced the **discovery of the FOP Gene in Nature Genetics in April 2006**
- 10,000 sq. ft. of shared research space in the Department of Orthopaedic Surgery
 - 3 principal investigators with 15 post-doctoral fellows, students, scientists, and staff
 - Funds spent on research – approx. \$1.5 million/year
 - 75% from FOP family fundraising and donations
 - 25% from institutional support (NIH/NIAMS, Orthopaedic Research and Education Foundation)



Characteristic bone formation: Note the ribbon of bone extending from the right hip, up the back, and into his right arm.